

# **NPUAP Pressure Ulcer Stages/Categories**

The National Pressure Ulcer Advisory Panel redefined the definition of a pressure ulcer and the stages of pressure ulcers in 2007, including the original 4 stages and adding 2 stages on deep tissue injury and unstageable pressure ulcers. This work was the culmination of over 5 years of work beginning with the identification of deep tissue injury in 2001.

The staging system was defined by Shea in 1975 and provides a name to the amount of anatomical tissue loss. The original definitions were confusing to many clinicians and lead to inaccurate staging of ulcers associated or due to perineal dermatitis and those due to deep tissue injury.

The proposed definitions were refined by the NPUAP with input from an on-line evaluation of their face validity, accuracy clarity, succinctness, utility, and discrimination. This process was completed online and provided input to the Panel for continued work. The proposed final definitions were reviewed by a consensus conference and their comments were used to create the final definitions.

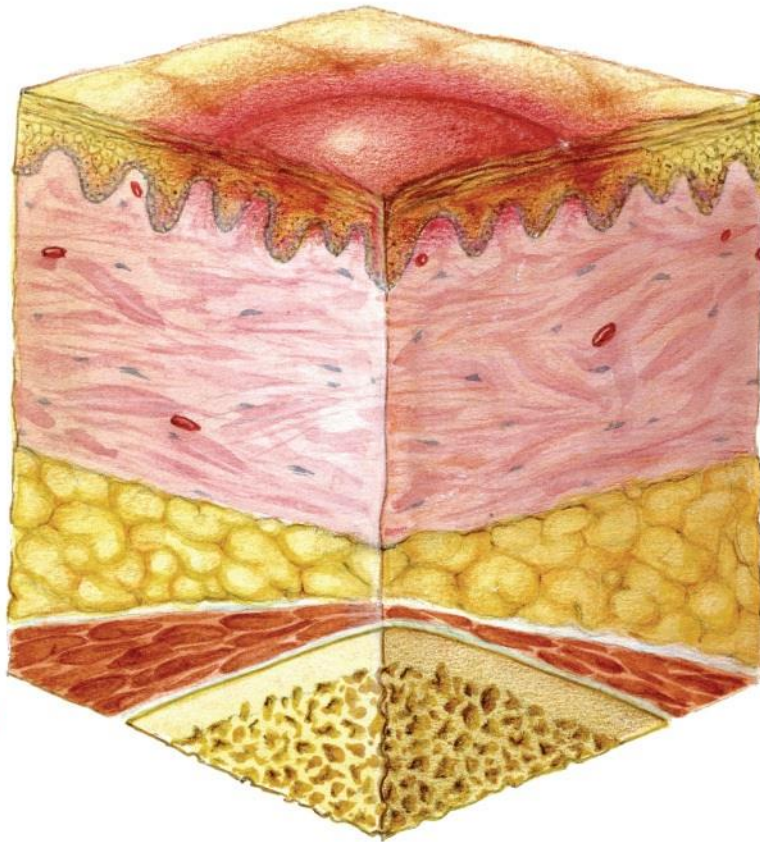
## **International NPUAP-EPUAP Pressure Ulcer Definition**

A pressure ulcer is localized injury to the skin and/or underlying tissue usually over a bony prominence, as a result of pressure, or pressure in combination with shear. A number of contributing or confounding factors are also associated with pressure ulcers; the significance of these factors is yet to be elucidated.

## **Pressure Ulcer Stages/Categories**

### **Category/Stage I: Non-blanchable erythema**

Intact skin with non-blanchable redness of a localized area usually over a bony prominence. Darkly pigmented skin may not have visible blanching; its color may differ from the surrounding area. The area may be painful, firm, soft, warmer or cooler as compared to adjacent tissue. Category I may be difficult to detect in individuals with dark skin tones. May indicate “at risk” persons.



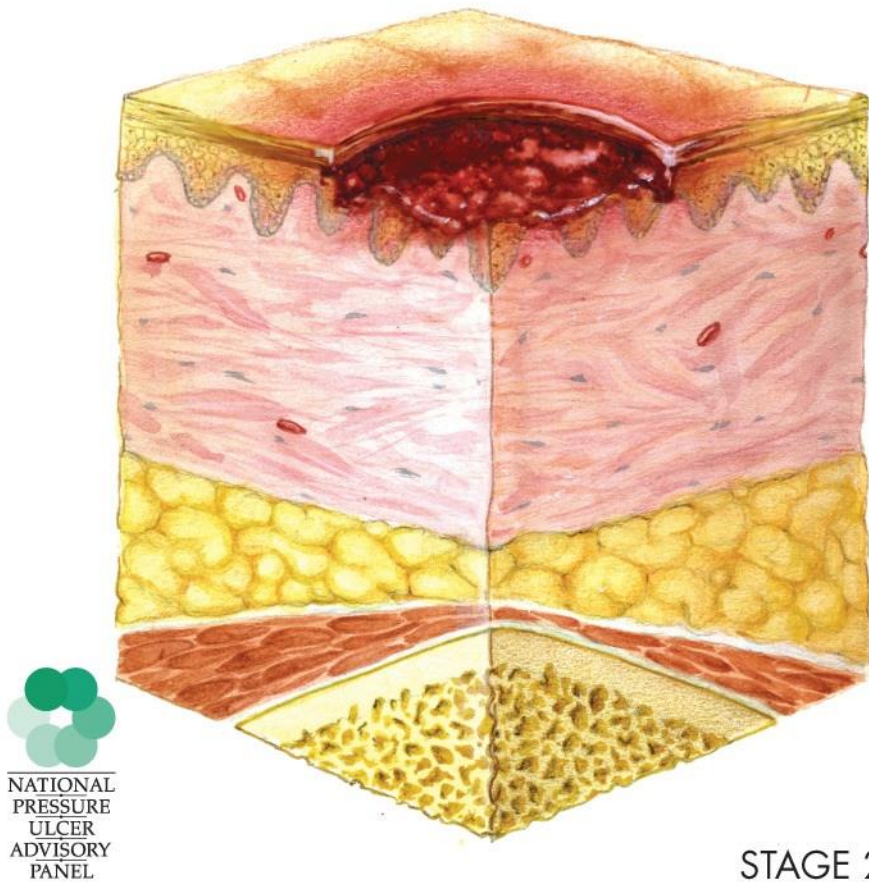
NATIONAL  
PRESSURE  
ULCER  
ADVISORY  
PANEL

STAGE 1

**Category/Stage II: Partial thickness**

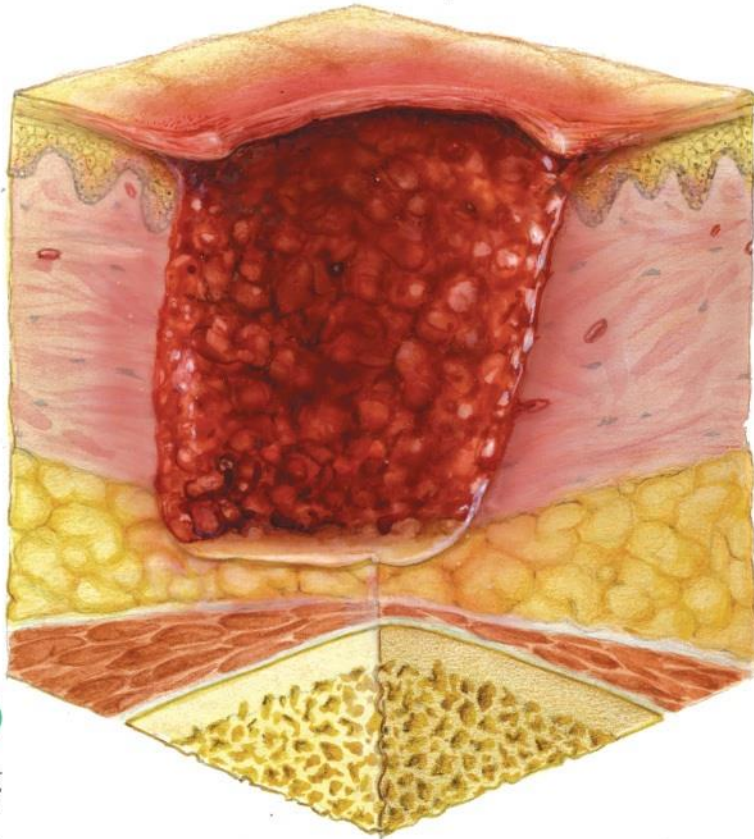
Partial thickness loss of dermis presenting as a shallow open ulcer with a red pink wound bed, without slough. May also present as an intact or open/ruptured serum-filled or sero-sanguinous filled blister. Presents as a shiny or dry shallow ulcer without slough or bruising\*. This category should not be used to describe skin tears, tape burns, incontinence associated dermatitis, maceration or excoriation.

\*Bruising indicates deep tissue injury.



**Category/Stage III: Full thickness skin loss**

Full thickness tissue loss. Subcutaneous fat may be visible but bone, tendon or muscle are *not* exposed. Slough may be present but does not obscure the depth of tissue loss. *May* include undermining and tunneling. The depth of a Category/Stage III pressure ulcer varies by anatomical location. The bridge of the nose, ear, occiput and malleolus do not have (adipose) subcutaneous tissue and Category/Stage III ulcers can be shallow. In contrast, areas of significant adiposity can develop extremely deep Category/Stage III pressure ulcers. Bone/tendon is not visible or directly palpable.

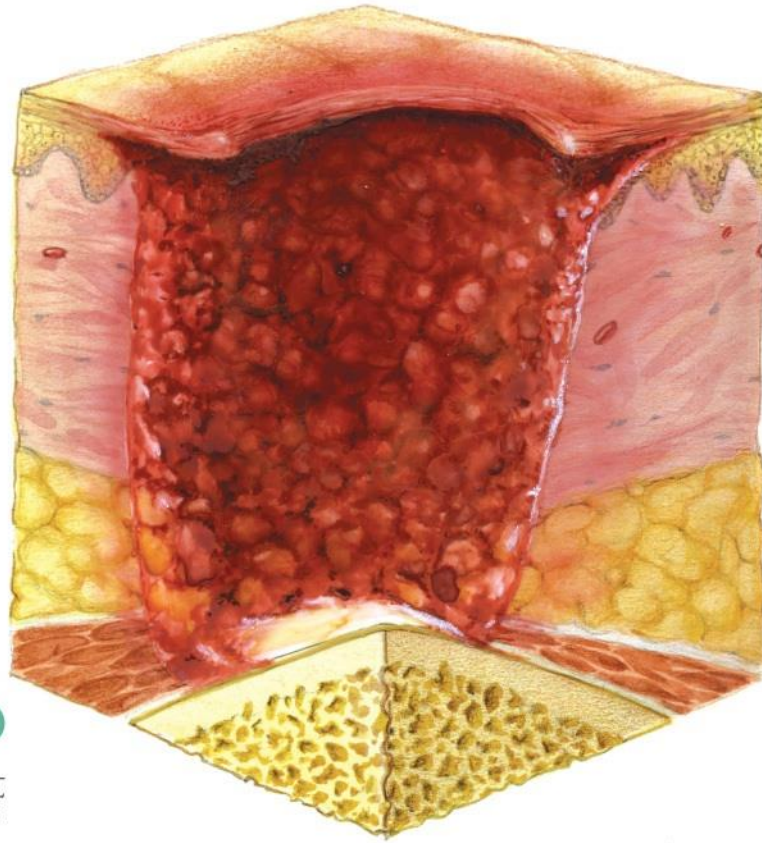


NATIONAL  
PRESSURE  
ULCER  
ADVISORY  
PANEL

STAGE 3

**Category/Stage IV: Full thickness tissue loss**

Full thickness tissue loss with exposed bone, tendon or muscle. Slough or eschar may be present. Often includes undermining and tunneling. The depth of a Category/Stage IV pressure ulcer varies by anatomical location. The bridge of the nose, ear, occiput and malleolus do not have (adipose) subcutaneous tissue and these ulcers can be shallow. Category/Stage IV ulcers can extend into muscle and/or supporting structures (e.g., fascia, tendon or joint capsule) making osteomyelitis or osteitis likely to occur. Exposed bone/muscle is visible or directly palpable.



STAGE 4

### **Additional Categories/Stages for the USA**

#### **Unstageable/Unclassified: Full thickness skin or tissue loss – depth unknown**

Full thickness tissue loss in which actual depth of the ulcer is completely obscured by slough (yellow, tan, gray, green or brown) and/or eschar (tan, brown or black) in the wound bed. Until enough slough and/or eschar are removed to expose the base of the wound, the true depth cannot be determined; but it will be either a Category/Stage III or IV. Stable (dry, adherent, intact without erythema or fluctuance) eschar on the heels serves as “the body’s natural (biological) cover” and should not be removed.

#### **Suspected Deep Tissue Injury – depth unknown**

Purple or maroon localized area of discolored intact skin or blood-filled blister due to damage of underlying soft tissue from pressure and/or *shear*. The area may be preceded by tissue that is painful, firm, mushy, boggy, warmer or cooler as compared to adjacent tissue. Deep tissue injury may be difficult to detect in individuals with dark skin tones. Evolution may include a thin blister over a dark wound bed. The wound may further evolve and become covered by thin eschar. Evolution may be rapid exposing additional layers of tissue even with optimal treatment